



## Nagoya City University Academic Repository

<b>Title</b>	Structural and Functional Analyses of Retinal Ischemia in Eyes with Retinal Vein Occlusion: Relationship with Macular Edema or Microaneurysm Formation
<b>Author(s)</b>	Taneto Tomiyasu, Yoshio Hirano, Norihiro Suzuki, Yuya Esaki, Yusuke Yasuda, Akiyoshi Uemura, Tsutomu Yasukawa, Munenori Yoshida, Yuichiro Ogura
<b>Citation</b>	Ophthalmic Research 61(4): 218 – 225
<b>Issue Date</b>	2019-04
<b>Right</b>	©2018 S.karger AG, This is the accepted manuscript version of the article. The formal published version is available at: <a href="https://doi.org/10.1159/000488496">https://doi.org/10.1159/000488496</a>
<b>Type</b>	article (author version)

<b>ORE493489 - Ophthalmic Res - ISSN 0030-3747 (for internal use only)</b>							
Code 3	PE	CE	Copy edited	Figures	Tables	Suppl. mat.	Typesetting
ORE	gs	oc	8.10.18	4	2		bk
Language	E	Second Language		Third Language	Template_Art		ZU

Internal info:



Queries to the author	<ol style="list-style-type: none"> <li>Please confirm that authors' names and initials have been identified correctly.</li> <li>Table 2: please explain ** ■■■.</li> <li>Please provide a Disclosure Statement regarding conflicts of interest.</li> </ol>
-----------------------	--

Article title	Structural and Functional Analyses of Retinal Ischemia in Eyes with Retinal Vein Occlusion: Relationship with Macular Edema or Microaneurysm Formation
Article title second language	
Article title third language	
Subtitle	
Short title	Structural and Functional Analyses of Retinal Ischemia in RVO
Section title	Research Article

Relation(s)	Example: Initials S.-J.	Given name Seo-Jin	Surname/Collaboration Park	Affiliation(s) a,b
2367438	T.	Taneto	Tomiyasu	
2367439	Y.	Yoshio	Hirano	
2367440	N.	Norihiro	Suzuki	
2367441	Y.	Yuya	Esaki	
2367442	Y.	Yusuke	Yasuda	
2367443	A.	Akiyoshi	Uemura	
2367444	T.	Tsutomu	Yasukawa	
2367445	M.	Munenori	Yoshida	
2367446	Y.	Yuichiro	Ogura	

Affiliation(s)	City	State	Country
Department of Ophthalmology and Visual Science, Nagoya City University Graduate School of Medical Sciences	Nagoya		Japan

Additional information	Presented at the 71st Annual Congress of Japan Clinical Ophthalmology (Tokyo, Japan) on October 13th, 2017.
------------------------	---

Corresponding author	Yoshio Hirano, MD, PhD
Full address	Department of Ophthalmology and Visual Science Nagoya City University Graduate School of Medical Sciences 1-Kawasumi, Mizuho-cho, Mizuho-ku, Nagoya 467-8601 (Japan)

E-Mail	E-Mail yoshio.hirano@gmail.com
--------	--------------------------------

Citation line	Journal			
	Ophthalmic Res			
10.1159/000493489	Article-Nr	493489	CCCode	
ISSN	0030-3747			
ISBN				

Received	Received: July 4, 2018
Accepted	Accepted after revision: September 3, 2018
Revised	
Published online	Published online: ■■■
Copyright statement	© 2018 S. Karger AG, Basel
Copyright description	

Keywords	Keywords
	Optical coherence tomography angiography Retinal thickness Microperimetry Retinal vein occlusion Macular edema Microaneurysm

Keywords Second Language	
--------------------------	--

Keywords Third Language	
-------------------------	--

Abbreviations	
---------------	--

Abstract	Abstract
----------	----------

**Purpose:** To study the structural and functional changes of retinal ischemia and investigate their association with macular edema (ME) or microaneurysm (MA) formation in eyes with retinal vein occlusion (RVO). **Methods:** Sixty eyes of 30 patients (27 eyes with branch [b]RVO, 3 with central RVO, and 30 fellow eyes) were retrospectively reviewed. Optical coherence tomography (OCT), OCT angiography (OCTA), and microperimetry were performed simultaneously to measure retinal thickness and sensitivity. The presence of ME or MA was also assessed using OCT and fluorescein angiography. **Results:** The mean retinal sensitivity in the nonperfused areas (NPAs) deteriorated, and this was significantly ( $r = -0.379$ ,  $p = 0.0391^*$ ) and inversely correlated with duration from disease onset. ME and MA were unlikely to be observed around the area where the retinal sensitivity decreased. In the NPAs, the mean retinal thickness of the superficial capillary plexus (SCP) ( $p < 0.0001$ ), deep capillary plexus (DCP) ( $p =$

---

0.0323), and outer retina ( $p = 0.0008$ ) were significantly thinner than those in the fellow eyes, respectively. Multivariate regression analysis revealed that the thicknesses of the DCP ( $\beta$ : 0.3107,  $p = 0.0007$ ) and outer retina ( $\beta$ : 0.3482,  $p = 0.0001$ ) were the independent correlative factors of the retinal sensitivity, but that SCP thickness was not. **Conclusion:** Deep retinal thinning in NPAs was correlated significantly with a decreased retinal sensitivity, which might be a negative predictor of ME and MA in eyes with RVO.

---

Abstract Second Language

---

Abstract Third Language

---

Key Messages

---

---

---

Body

---

## Introduction

Retinal vein occlusion (RVO) causes various retinal microangiopathies, one of which is retinal ischemia. Ischemia usually leads to hypoxia, followed by upregulation of vascular endothelial growth factor (VEGF). In fact, several reports have shown overexpression of VEGF in eyes with RVO [1, 2], which can lead to vision-threatening conditions such as macular edema (ME) [3], microaneurysm (MA) [4], and retinal neovascularization [3]. Therefore, investigation of retinal ischemia might be important when considering treatment for patients with RVO.

Finkelstein [5] previously reported that ischemic ME is associated with good visual outcomes because the ME is often transient. In this report, however, only fundus examination

and fluorescein angiography (FA) were used to assess retinal ischemia and ME. For example, nonperfused areas (NPAs) on FA images were defined as retinal ischemia and the presence of ME was confirmed based on these images and fundus examination. We recently reported that optical coherence tomography angiography (OCTA) is more useful to detect NPAs in eyes with branch (B)RVO than FA because OCTA is free from dye and provides higher-resolution images [6, 7]. For assessment of ME, OCT enables measurements of the thickness of the whole retina but also of each retinal layer. Moreover, only visual acuity (VA), which usually represents a central vision, was used for analysis of visual function in our previous study, while microperimetry enables assessment of fundus-correlated visual function with an eye tracker. Therefore, with OCT, OCTA, and microperimetry, it is possible to perform more detailed analyses of retinal ischemia, ME, and visual function, leading to a better understanding.

Several reports [8, 9] have been published recently that evaluate the relationship between macular ischemia and visual function using OCT, OCTA, and microperimetry in eyes with RVO. However, the relationship between retinal ischemia and ME or MA was not examined, and the thickness of the entire retina was measured, not of each retinal layer. Moreover, retinal sensitivity was measured using MP-1 (Nidek, Gamagori, Japan), which limits the range of stimulus intensities to 0–20 dB. A recently developed microperimeter, MP-3 (Nidek), provides a wider range of stimulus intensities (0–34 dB) than the previous-generation MP-1, enabling a precise evaluation of visual function.

In this study, we aimed to evaluate structural and functional analyses of retinal ischemia in eyes with RVO using multiple modalities including OCT, OCTA, and MP-3. The relationship with ME or MA formation was assessed to study the pathological significance of retinal ischemia in eyes with RVO.

## **Methods**

### *Patients*

This was a retrospective, observational, and consecutive case series conducted at Nagoya City University (NCU) Hospital from August 2016 to October 2016. The NCU Institutional Review Board approved the study protocol (No. 60160087). The clinical trial was registered in UMIN-CTR (UMIN-ID: UMIN000025883). All experiments were performed in accordance with the Declaration of Helsinki. All patients provided written informed consent to participate in this study.

Patients with eyes with ME after RVO, who completed MP-3 measurements, and who gave their consent for the study were included. Patients with other retinal diseases, poor-quality images, ME with a retinal thickness of  $>400\ \mu\text{m}$ , serous retinal detachment, or without NPAs were excluded.

All patients underwent ophthalmic examinations including measurement of best-corrected VA, axial length (IOL Master 500, Carl Zeiss, Dublin, CA, USA), indirect ophthalmoscopy, fundus photography, OCT (Cirrus HD-OCT, Carl Zeiss), OCTA (RS-3000 Advance, Nidek), microperimetry (MP-3, Nidek), FA/indocyanine green angiography (ICGA) using confocal scanning laser ophthalmoscopy (Heidelberg Retina Angiography 2, Heidelberg Engineering, Heidelberg, Germany), and wide-field FA/ICGA (Optos California, Optos, Dunfermline, Scotland, UK). All eyes were diagnosed and the subtype or perfusion status was determined using these multiple modalities.

### *Evaluation of Retinal Ischemia Using Multiple Modalities*

MP-3 was used to measure retinal sensitivity as previously described [10]. Two experienced examiners performed all the tests. A custom-designed grid was used to examine 33 stimulus locations covering central  $5^\circ$ , similar to  $3 \times 3\ \text{mm}$  sections centered on the fovea (Fig. 1a, b). After completion of the test, fundus images with retinal sensitivity values (MP-3 images) were transferred to the OCTA system.

OCTA images were captured in  $3 \times 3\ \text{mm}$  sections centered on the fovea as well (Fig. 1c–e). The OCTA and MP-3 images were superimposed by matching retinal vessels on the

OCTA system (Fig. 1g), enabling assessment of the retinal sensitivity in NPAs which was defined on OCTA images. The mean retinal sensitivity was compared among fellow eyes, perfused areas, and NPAs in RVO eyes.

Retinal thicknesses were measured on OCTA at all MP-3 measurement points. They included the entire retina, from the internal limiting membrane (ILM) to the retinal pigment epithelium (RPE); the retinal superficial capillary plexus (SCP), from the ILM to the inner plexiform layer (IPL); the retinal deep capillary plexus (DCP), from the inner nuclear layer (INL) to the outer plexiform layer (OPL); and the outer retina, from the outer nuclear layer (ONL) to the RPE. Data from the foveal avascular zone (FAZ) were excluded similar to those of retinal sensitivity. Software provided by Nidek staff enabled measurement of each thickness automatically as well as a comparison of the different thicknesses. The relationship between retinal sensitivity and retinal thickness also was evaluated.

#### *Detection of ME and MAs*

ME was defined as a retinal thickness  $>350\ \mu\text{m}$  on the OCT color map (Fig. 1h). MAs were detected using indirect ophthalmoscopy, fundus photography, OCTA, FA, and ICGA. FA was superior to OCTA in detecting MAs as previously reported [6]. Moreover, leaky MAs were well detected on ICGA because of less dye leakage (Fig. 1i, j) [11, 12]. Fresh MAs were sometimes not detected on ICGA, although the reason was not clear. Therefore, if there was disagreement about judgement of MAs, the FA measurement had priority. Two retinal specialists (T.T. and Y.H.) who were masked to the retinal sensitivity, determined whether ME or MA was observed around each MP-3 measurement point within 3 months from MP-3 measurement.

#### *Grouping of the Location of MP-3 Measurement Points in NPAs*

The MP-3 measurement points in NPAs were divided into 3 groups: those in the center (zone A), those within  $300\ \mu\text{m}$  from the perfused area (zone B), and those near the FAZ (zone C) (Fig. 1f). If the point could not be categorized due to the zones overlapping, it was included in

all of them. Mean retinal sensitivity and frequency of ME or MA formation of the 3 groups were compared.

### *Treatments*

Intravitreal injections of the anti-VEGF agents, ranibizumab (Lucentis, Novartis, Bülach, Switzerland) for eyes with BRVO and aflibercept (Eylea, Bayer, Berlin, Germany) for eyes with CRVO, were used to treat ME after RVO. Patients who did not want anti-VEGF therapy because of the cost or previous cerebral and/or cardiovascular events received sub-Tenon's capsule injection of triamcinolone acetonide (Kenacort, Bristol-Myers, Tokyo, Japan). Additional injections were applied for recurrent or residual ME when the central retinal thickness exceeded 250  $\mu\text{m}$ . Scatter laser photocoagulation was performed for retinal neovascularization and/or NPAs >5 disk diameters for eyes with BRVO and >10 disk areas for eyes with CRVO.

### *Statistical Analysis*

VA was measured using Landolt C charts and converted to a logarithm of the minimal angle of resolution (logMAR) for statistical analyses. Spearman's rank correlation coefficient was used to evaluate a correlation between retinal sensitivity and VA, duration after disease onset, and retinal thickness. Unpaired *t* test was used to compare retinal sensitivity with and without ME or MAs. Post hoc Bonferroni correction was used to compare retinal sensitivity. Multivariate regression analysis was performed to detect factors correlative of retinal sensitivity. Independent  $\chi^2$  test was used to compare the presence of ME and MA formation.  $p < 0.05$  was considered statistically significant.

## **Results**

### *Patient Characteristics and Retinal Sensitivity*

Sixty eyes of 30 patients (15 men and 15 women) were enrolled, including 27 eyes with BRVO, 3 with CRVO, and 30 fellow eyes. The patient characteristics are shown in [Table 1](#).



Of the 990 MP-3 measurement points (30 RVO eyes × 33 points), 193 were detected in the NPAs, 598 in the perfused areas, and 199 in the FAZ, respectively. The mean retinal sensitivity values in the fellow eyes, perfused areas, and NPAs of the eyes with RVO were  $27.7 \pm 4.2$ ,  $26.4 \pm 5.1$ , and  $17.8 \pm 9.4$  dB, respectively (Fig. 2a). The retinal sensitivity levels in eyes with RVO, even in the perfused areas, were significantly lower than those in the fellow eyes. Figure 2b shows the relationship between duration after disease onset and mean retinal sensitivity in the NPAs in each RVO eye. The mean retinal sensitivity in the NPAs was correlated inversely with duration after disease onset ( $r = -0.379$ ,  $p = 0.0391$ ).

#### *Relationship between Retinal Sensitivity and ME or MA*

Figure 2c, d show the retinal sensitivity with and without ME or MA around the MP-3 measurement points. The mean retinal sensitivity of points where ME was observed was significantly ( $p < 0.0001$ ) higher than that of the other points. Similarly, the mean retinal sensitivity around the MAs was significantly ( $p < 0.0001$ ) higher than those of the other points. Taken together, the retinal sensitivity was correlated positively with ME and MA formation.

#### *Relationship between Retinal Sensitivity and Retinal Thickness*

Figure 3 shows the relationship between retinal sensitivity and each layer thickness. Figure 3a is a schema of each retinal layer. All mean thicknesses, i.e., of the whole retina, SCP, DCP, and outer retina, in the NPAs were thinner than in the perfused areas and the fellow eyes (Fig. 3b–e). The retinal sensitivity was correlated significantly and positively with the thicknesses of the entire retina ( $r = 0.24770$ ,  $p = 0.0034^{**}$ ; Fig. 3f), the DCP ( $r = 0.1744$ ,  $p = 0.0400^{*}$ ; Fig. 3h), and the outer retina ( $r = 0.2937$ ,  $p = 0.0004^{**}$ ; Fig. 3i), but not with that of the SCP ( $r = 0.1513$ ,  $p = 0.0753$ ; Fig. 3g). Multivariate analysis revealed that both the DCP and outer retinal thicknesses were associated with retinal sensitivity (Table 2).

#### *Relationship between Location in NPAs and Retinal Sensitivity, ME, and MA*

Figure 4 shows the mean retinal sensitivity in each group. The mean retinal sensitivity in zone B was significantly higher than in zone A ( $p = 0.0013$ ) and zone C ( $p = 0.0277$ ) (Fig. 4a).

MAAs were observed significantly more frequently in zone B ( $p < 0.0001^{**}$ ) (Fig. 4b) but ME was not ( $p = 0.115$ ) (Fig. 4c).

## Discussion

First, we found the mean retinal sensitivity in the perfused areas and NPAs were significantly lower than in the fellow eyes, possibly because the VA in the eyes with RVO decreased. We also found an inverse correlation between the mean retinal sensitivity in the NPAs and duration after disease onset, suggesting that the function of old NPAs might have deteriorated.

Second, we found that all of the SCP, DCP, and outer retina in the NPAs were thinner than those in the perfused areas and the fellow eyes. RVO usually causes inner retinal ischemia followed by an inner retinal thinning. In fact, a thinning of the ganglion cell complex has been reported in eyes with BRVO [13], consistent with our results. Furthermore, we found that the thicknesses of the DCP and outer retina were correlated with the retinal sensitivity. Kadomoto et al. [8] recently reported that parafoveal NPA size was more associated with the macular sensitivity than ellipsoid zone (EZ) integrity in eyes without ME after BRVO. However, they defined macular sensitivity as mean value from a total 29 points in the central  $6^\circ$  area and the EZ integrity as defect length of vertical EZ band through the center of the fovea. Therefore, the influence of the unaffected area was not eliminated. In our study, NPAs were examined apart from the perfused areas and each point in the NPA was also independently examined. A previous report [14] showed that the EZ integrity affected visual function in BRVO, so the thickness of outer retina also might affect the retinal sensitivity.

We also found that the retinal sensitivity in the areas where ME and MAAs were not observed was significantly lower than in the other areas. VEGF levels were upregulated in eyes with RVO [1, 2], leading to ME [3] or MA formation [4, 15]. Previous studies have also reported that anti-VEGF therapy could reduce ME [16, 17] and MA formation [4] in patients with RVO,

suggesting that VEGF levels are related closely to ME and MA formation. VEGF-A affects neuronal growth, differentiation, and survival [18]. In addition, the receptors for VEGF-A were present in normal retinal neuron cells in animal models, especially in the DCP [19, 20].

Therefore, when the DCP is intact, VEGF expression might be upregulated in the condition of hypoxia such as RVO, leading to ME or MA formation.

The Branch Vein Occlusion Study Group (BVOS) established laser photocoagulation as the gold standard for treating ME associated with BRVO before the introduction of anti-VEGF therapy [21]. Tomomatsu et al. [22] reported that laser photocoagulation for peripheral NPAs prevented the recurrence of ME in BRVO. However, Campochiaro et al. [23] reported that scatter photocoagulation did not reduce macular edema in BRVO. Retinal sensitivity in the NPAs was not examined in these reports. Our results showed that, if the area in the NPAs where the retinal sensitivity decreased did not cause ME, laser photocoagulation applied to reduce ME might be fruitless.

We then found that the retinal sensitivity of points in zone B was significantly higher than in the other zones. We also showed an inverse correlation between the mean retinal sensitivity in the NPAs and the duration after disease onset. Taken together, the NPA at the border might be relatively fresh and the retinal sensitivity remains compared with that in the center of the NPAs. In the natural course of RVO, NPAs progress due to upregulation of VEGF [24]. We speculate that the NPA might spread gradually from the edge due to upregulation of VEGF. We found that MAs were detected significantly and more frequently in zone B, where the retinal sensitivity remained. MAs have been detected frequently at the edges of NPAs in eyes with RVO, consistent with the hypothesis that they are a secondary reaction to hypoxia and increased local VEGF concentration [25], which confirms our results.

Regarding the location of ME, we found no significant difference across the 3 zones, i.e., zones B and C were more common locations of ME than zone A. ME is usually observed at the center of the macula because there are no venules that drain back the extravascular fluid [25]. Therefore, the incidence of ME in zone C might be comparable to that in zone B.

Our study had several limitations. First, the sample size was small and the study design was retrospective. Second, the captured area was too small. Third, the patients received different treatments. Fourth, the VEGF levels in the vitreous humor of each patient should be measured.

In conclusion, our results showed that both the inner and outer retina became thinner and the retinal sensitivity decreased in NPAs in eyes with RVO. Both DCP and outer retinal thickness were correlated with retinal sensitivity. Furthermore, ME or MA was unlikely to be formed in severe retinal ischemic lesions. A future prospective, randomized, controlled study with larger samples is needed to confirm these results.

## **Acknowledgements**

We thank Fumie Shibuya, Yasuyo Matsuda, Sayaka Oshio, and Soushi Shimizu (Nagoya City University Graduate School of Medical Sciences) for their contributions to data collection. We also thank Kenya Ozaki (Nidek Technologies, Gamagori, Japan) for supporting the data analysis and providing the software with which the thickness of each layer can be measured. The authors thank Medical International for professional medical English editing. Nidek Technologies provided an OCT angiography system (RS-3000 Advance) and microperimetry system (MP-3) to Nagoya City University to support data collection.

## **Disclosure Statement**

The authors declare that each of authors has no relevant interests that relate to the research described in this paper.

## **Funding Sources**

This study was supported by a Grant-in-Aid for Young Scientists (B) 17K16977 (T.T.) and a Grant-in-Aid for Scientific Research (C) 18K09416 (Y.H.), 16K11293 (T.Y.), and Scientific Research (B) 16H05155 (A.U.), 18H02958 (Y.O.) from the Japan Society for the Promotion of Science, Tokyo, Japan. Y.H. also was supported by Aichi Health Promotion of Science, Nagoya, Japan and the Eye Research Foundation for the Aged, Odawara, Japan. This work was supported by Nidek Technologies. Y.H. received a lecture fee from Nidek Technologies.

## Author Contributions

T.T., Y.H., N.S., Y.E., and Y.Y. collected and analyzed the data. Y.H. wrote the main manuscript. A.U., T.Y., M.Y., and Y.O. supervised the work. All authors reviewed the manuscript.

## References

- 1 Aiello LP, Avery RL, Arrigg PG, Keyt BA, Jampel HD, Shah ST, et al. Vascular endothelial growth factor in ocular fluid of patients with diabetic retinopathy and other retinal disorders. [N Engl J Med](#). 1994 Dec;331(22):1480–7.
- 2 Noma H, Funatsu H, Yamasaki M, Tsukamoto H, Mimura T, Sone T, et al. Pathogenesis of macular edema with branch retinal vein occlusion and intraocular levels of vascular endothelial growth factor and interleukin-6. [Am J Ophthalmol](#). 2005 Aug;140(2):256–61.
- 3 Ozaki H, Hayashi H, Vinorez SA, Moromizato Y, Campochiaro PA, Oshima K. Intravitreal sustained release of VEGF causes retinal neovascularization in rabbits and breakdown of the blood-retinal barrier in rabbits and primates. [Exp Eye Res](#). 1997 Apr;64(4):505–17.
- 4 Tomiyasu T, Hirano Y, Yoshida M, Suzuki N, Nishiyama T, Uemura A, et al. Microaneurysms cause refractory macular edema in branch retinal vein occlusion. [Sci Rep](#). 2016 Jul;6(1):29445.
- 5 Finkelstein D. Ischemic macular edema. Recognition and favorable natural history in branch vein occlusion. [Arch Ophthalmol](#). 1992 Oct;110(10):1427–34.
- 6 Suzuki N, Hirano Y, Yoshida M, Tomiyasu T, Uemura A, Yasukawa T, et al. Microvascular abnormalities on optical coherence tomography angiography in macular

- edema associated with branch retinal vein occlusion. [Am J Ophthalmol](#). 2016 Jan;161:126–32.e1.
- 7 Suzuki N, Hirano Y, Tomiyasu T, Esaki Y, Uemura A, Yasukawa T, et al. Retinal hemodynamics seen on optical coherence tomography angiography before and after treatment of retinal vein occlusion. [Invest Ophthalmol Vis Sci](#). 2016 Oct;57(13):5681–7.
- 8 Kadomoto S, Muraoka Y, Ooto S, Miwa Y, Iida Y, Suzuma K, et al. Evaluation of macular ischemia in eyes with branch retinal vein occlusion: an optical coherence tomography angiography study. [Retina](#). 2018 Feb;38(2):272–82.
- 9 Ghashut R, Muraoka Y, Ooto S, et al. Evaluation of macular ischemia in eyes with central retinal vein occlusion: an optical coherence tomography angiography study. [Retina](#). 2018 Aug;38(8):1571–1580.
- 10 Hariri AH, Tepelus TC, Akil H, Nittala MG, Sadda SR. Retinal Sensitivity at the Junctional Zone of Eyes With Geographic Atrophy Due to Age-Related Macular Degeneration. [Am J Ophthalmol](#). 2016 Aug;168:122–8.
- 11 Hirano Y, Yasukawa T, Usui Y, Nozaki M, Ogura Y. Indocyanine green angiography-guided laser photocoagulation combined with sub-Tenon's capsule injection of triamcinolone acetonide for idiopathic macular telangiectasia. [Br J Ophthalmol](#). 2010 May;94(5):600–5.
- 12 Paques M, Philippakis E, Bonnet C, Falah S, Ayello-Scheer S, Zwillinger S, et al. Indocyanine-green-guided targeted laser photocoagulation of capillary macroaneurysms in macular oedema: a pilot study. [Br J Ophthalmol](#). 2017 Feb;101(2):170–4.
- 13 Lim HB, Kim MS, Jo YJ, Kim JY. Prediction of retinal ischemia in branch retinal vein occlusion: spectral-domain optical coherence tomography study. [Invest Ophthalmol Vis Sci](#). 2015 Oct;56(11):6622–9.
- 14 Ota M, Tsujikawa A, Murakami T, Yamaike N, Sakamoto A, Kotera Y, et al. Foveal photoreceptor layer in eyes with persistent cystoid macular edema associated with branch retinal vein occlusion. [Am J Ophthalmol](#). 2008 Feb;145(2):273–80.

- 15 Tolentino MJ, Miller JW, Gragoudas ES, Jakobiec FA, Flynn E, Chatzistefanou K, et al. Intravitreal injections of vascular endothelial growth factor produce retinal ischemia and microangiopathy in an adult primate. [Ophthalmology](#). 1996 Nov;103(11):1820–8.
- 16 Brown DM, Campochiaro PA, Bhisitkul RB, Ho AC, Gray S, Saroj N, et al. Sustained benefits from ranibizumab for macular edema following branch retinal vein occlusion: 12-month outcomes of a phase III study. [Ophthalmology](#). 2011 Aug;118(8):1594–602.
- 17 Thach AB, Yau L, Hoang C, Tuomi L. Time to clinically significant visual acuity gains after ranibizumab treatment for retinal vein occlusion: BRAVO and CRUISE trials. [Ophthalmology](#). 2014 May;121(5):1059–66.
- 18 Jin KL, Mao XO, Greenberg DA. Vascular endothelial growth factor: direct neuroprotective effect in in vitro ischemia. [Proc Natl Acad Sci USA](#). 2000 Aug;97(18):10242–7.
- 19 Kim I, Ryan AM, Rohan R, Amano S, Aguilar S, Miller JW, et al. Constitutive expression of VEGF, VEGFR-1, and VEGFR-2 in normal eyes. [Invest Ophthalmol Vis Sci](#). 1999 Aug;40(9):2115–21.
- 20 Gilbert RE, Vranes D, Berka JL, Kelly DJ, Cox A, Wu LL, et al. Vascular endothelial growth factor and its receptors in control and diabetic rat eyes. [Lab Invest](#). 1998 Aug;78(8):1017–27.
- 21 The Branch Vein Occlusion Study Group. Argon laser photocoagulation for macular edema in branch vein occlusion. [Am J Ophthalmol](#). 1984 Sep;98(3):271–82.
- 22 Tomomatsu Y, Tomomatsu T, Takamura Y, Gozawa M, Arimura S, Takihara Y, et al. Comparative study of combined bevacizumab/targeted photocoagulation vs bevacizumab alone for macular oedema in ischaemic branch retinal vein occlusions. [Acta Ophthalmol](#). 2016 May;94(3):e225–30.
- 23 Campochiaro PA, Hafiz G, Mir TA, Scott AW, Solomon S, Zimmer-Galler I, et al. Scatter photocoagulation does not reduce macular edema or treatment burden in patients with retinal vein occlusion: the RELATE Trial. [Ophthalmology](#). 2015 Jul;122(7):1426–37.

- 24 Campochiaro PA, Bhisitkul RB, Shapiro H, Rubio RG. Vascular endothelial growth factor promotes progressive retinal nonperfusion in patients with retinal vein occlusion. *Ophthalmology*. 2013 Apr;120(4):795–802.
- 25 Browning DJ. Retinal vein occlusions. In: Browning, DJ, editor. *Pathophysiology of Retinal Vein Occlusions*. New York: Springer; 2012. pp. 33–72 (Springer, 2012).

Appendix after References (Editorial Comments)

#### Legend(s)

Fig. 1. A multimodal imaging from an eye with branch retinal vein occlusion (BRVO). **a** Fundus-monitoring microperimetry (MP-3). The retinal sensitivity was evaluated at 33 stimulus points covering the central 5°. **b** A magnified image within the central 5° of **a**. **c–e** Optical coherence tomography angiograms (OCTAs) (3 × 3 mm) centered on the fovea. **c** Retinal superficial capillary plexus. **d** Retinal deep capillary plexus. **e** A merged image of the entire retina from the internal limiting membrane to the retinal pigment epithelium. **f** Inverted colors of the OCTA image with black on white. Red frame, nonperfused areas (NPAs); white lines, points in the center of the NPAs (zone A); yellow lines, points at the border between the NPAs and perfused area (zone B); blue lines, points near the foveal avascular zone (zone C). **g** A superimposed image of the MP-3 and OCTA. The MP-3 measurement points in the NPAs were divided into the abovementioned 3 groups (white, yellow, and blue circles). **h** OCT color map. Red area indicates macular edema. **i** A fluorescein angiogram. **j** An indocyanine green angiogram. Hyperfluorescent spots (arrows) indicated microaneurysms.

Fig. 2. Retinal sensitivity in the nonperfused areas (NPAs) and the relationship with macular edema (ME) or microaneurysm (MA). **a** Mean retinal sensitivity levels in eyes with retinal vein occlusion (RVO), even in the perfused areas, were significantly (\*\*  $p < 0.0001$ ) lower than in the fellow eyes. Data in foveal avascular zone were excluded. **b** Relationship between mean retinal sensitivity in NPAs in each RVO eye and the duration after disease



onset. There was an inverse correlation between the retinal sensitivity and the time after disease onset. The retinal sensitivity with (+) and without (–) ME (**c**) and MA (**d**) around the microperimetry measurement points. The retinal sensitivity at the points with ME or MA (\*\*  $p < 0.0001$ ) are significantly higher than at those without ME or MA. Error bars represent standard deviations.

Fig. 3. The relationship between retinal sensitivity and retinal thickness. **a** Schema of the human retina. SCP, superficial capillary plexus; DCP, deep capillary plexus; ILM, internal limiting membrane; NFL, nerve fiber layer; GCL, ganglion cell layer; IPL, inner plexiform layer; INL, inner nuclear layer; OPL, outer plexiform layer; ONL, outer nuclear layer; PR, photoreceptor; RPE, retinal pigment epithelium. **b–e** The thickness of each layer was measured in fellow eyes and eyes with retinal vein occlusion (RVO), i.e., that of the entire retina, from the ILM to the RPE (**b**); the retinal SCP, from the ILM to the IPL (**c**); the retinal DCP, from the INL to the OPL (**d**); and the outer retina, from the ONL to the RPE (**e**). All retinal layers in NPAs were thinner than in perfused areas. **f–i** The relationship between retinal sensitivity and retinal thickness of each layer. **f** The entire retinal thickness is correlated significantly and positively with the retinal sensitivity. In particular, the DCP thickness (**h**) and outer retinal thickness (**i**) are correlated significantly with the retinal sensitivity but the SCP thickness (**g**) is not.

Fig. 4. The relationship between location in the nonperfused areas and retinal sensitivity, macular edema (ME), and microaneurysm (MA). **a** Mean retinal sensitivity in zones A–C. In zone B, it was significantly higher than in the other groups (\*\*  $p = 0.0013$  vs. zone A; \*  $p = 0.0277$  vs. zone C). **b, c** The relationship between the location and ME (**b**) or MA (**c**). MAs were significantly more frequently observed in zone B, but this was not the case with ME.



**Table 1.** Patient characteristics

---

Age, years	68.3±9.1
Male/female	15/15
BRVO/CRVO	27/3 eyes
Subtype	
BRVO, macular/major	10/17 eyes
CRVO, CRVO/hemi-CRVO	1/2 eyes
Ischemic/nonischemic	13/17 eyes
Diabetes mellitus, yes/no/unknown	3/25/2
Hypertension, yes/no/unknown	13/15/2
Lens status, phakic/pseudophakic	23/7 eyes
logMAR VA	0.032±0.24
CRT, $\mu$ m	287±52
Axial length, mm	23.6±1.3
Duration between symptoms and MP-3 measurement, months	26.3±20
Duration between symptoms and FA/ICGA measurement, months	21.5±19
Treatment, anti-VEGF/steroid/PHC alone	22/5/3 eyes
Retinal PHC	
Yes/No	11/19 eyes
Direct PHC alone	4 eyes
Scatter PHC alone	3 eyes
Both	4 eyes

---

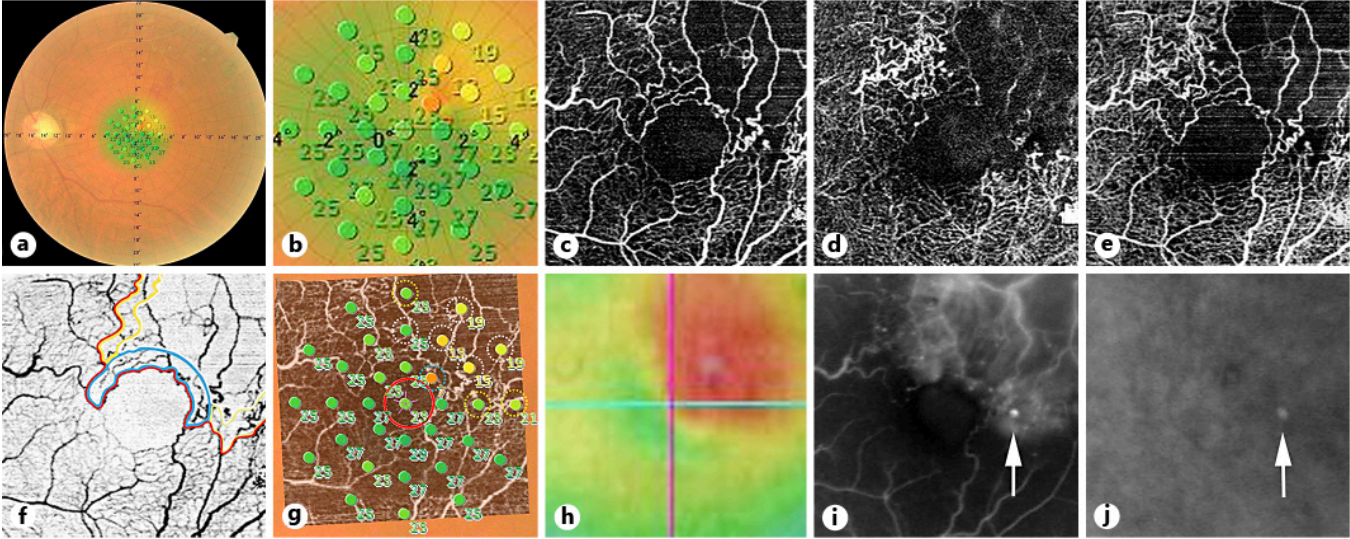
Values appear as mean  $\pm$  standard deviation or *n*, unless otherwise indicated. BRVO, branch retinal vein occlusion; CRVO, central retinal vein occlusion; logMAR, logarithm of the minimal angle of resolution; VA, visual acuity; CRT, central retinal thickness; MP-3, microperimetry-3; FA, fluorescein angiography, ICGA, indocyanine green angiography, VEGF, vascular endothelial growth factor; PHC, photocoagulation.

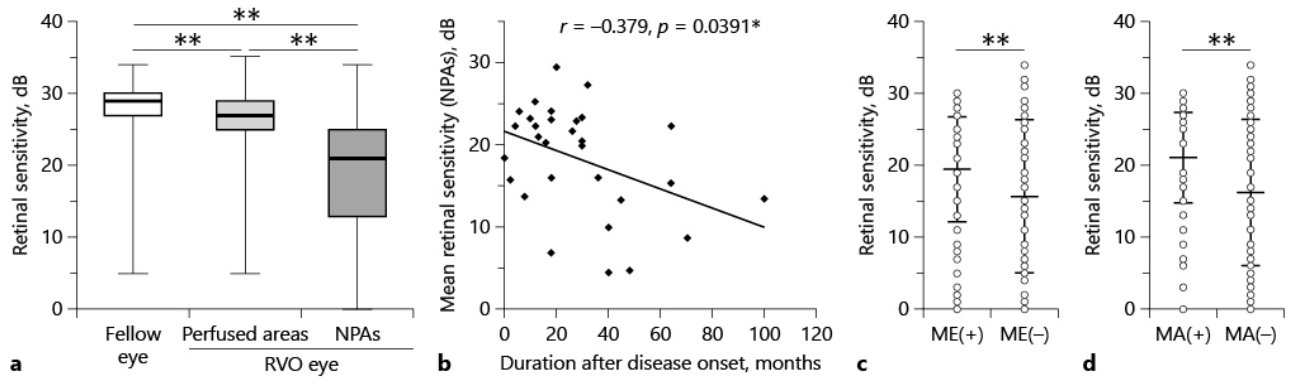
---

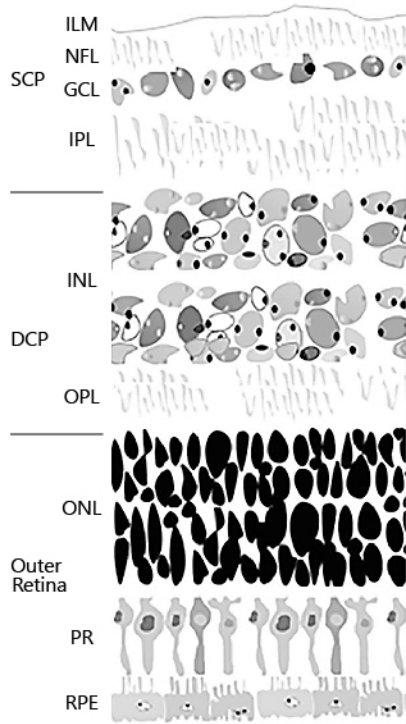
**Table 2.** Multivariate regression analysis to detect factors correlative of the retinal sensitivity

Factor	$\beta$	<i>p</i> value
Superficial capillary plexus thickness	0.1362	0.1171
Deep capillary plexus thickness	0.3107	0.0007**
Outer retinal thickness	0.3482	0.0001**

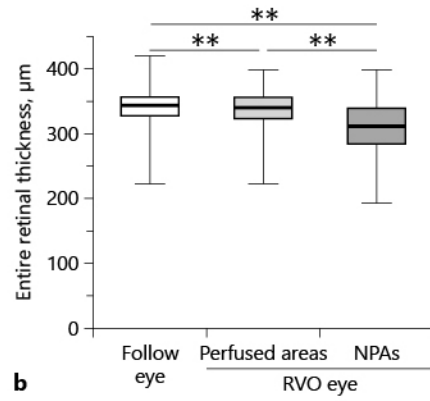
\*\* significant difference.



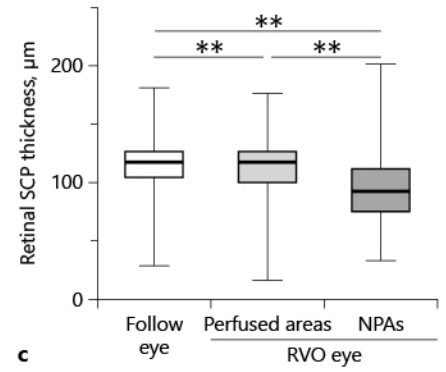




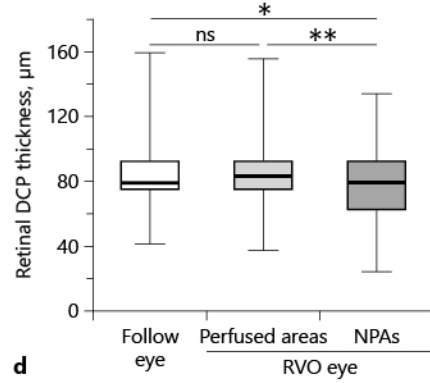
**a**



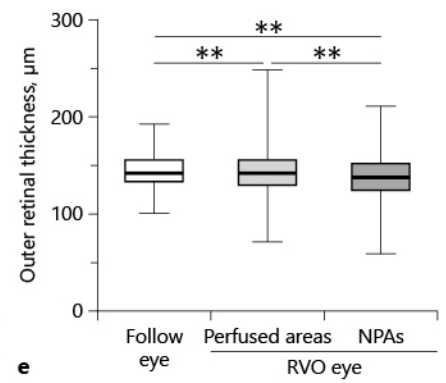
**b**



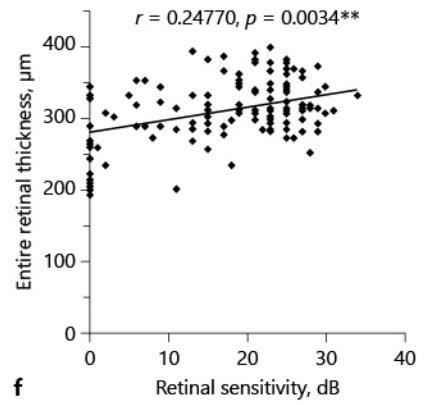
**c**



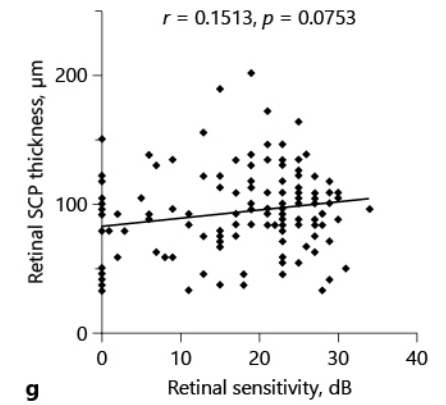
**d**



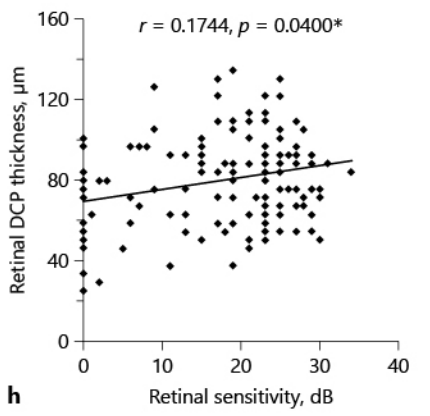
**e**



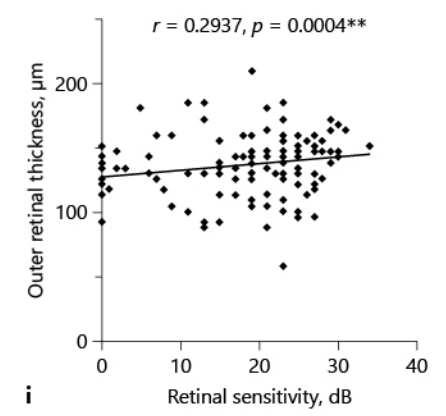
**f**



**g**

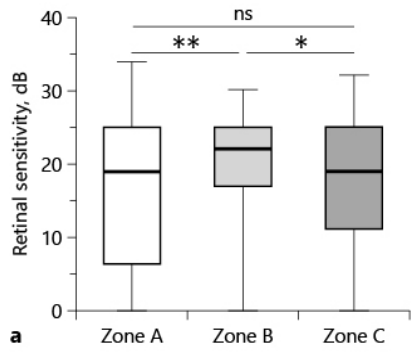


**h**



**i**

ore493489\_F04.jpg



ME	A	B	C
Yes	49	50	41
No	64	36	44
Total	113	86	85
%	43.3	58.1	48.2

**b**  $p = 0.115$ , Cramer V: 0.123

MA	A	B	C
Yes	20	47	18
No	93	39	67
Total	113	86	85
%	17.7	54.7	21.1

**c**  $p < 0.0001^{**}$ , Cramer V: 0.357